International Journal of Biomedical Investigation

Available Online: http://ijbi.edwiserinternational.com

Suppurative Chronic Osteomyelitis: Case Report

Araujo JB, Lima Fonseca KC, Queiroz Danda TF, de Sousa Teixeira AL and Azenha MR*

Academic of the Course of Dentistry, Faculty of Imperatriz-FACIMP, Brazil

Article info

Received 20 May 2018
Revised 22 June 2018
Published 28 June 2018

*Corresponding author: Dr. JB Araujo, Academic of the Course of Dentistry, Faculty of Imperatriz-FACIMP, Brazil. E-mail: jhonatajba@gmail.com

Abstract

The chronic suppurative osteomyelitis is an inflammation of infectious origin, which invades the bone marrow spaces, being able to reach the cortical bone and the Harvesian system, extending until the periosteum, causing the decrease of the blood supply, leading to ischemia, and subsequently to a tissue necrosis of the bone. Its etiology is multifactorial, whose odontogenic infections are the most common causes, presenting difficult diagnosis and complex treatment, the prognosis being, in most cases, unpredictable. Fever, pain, edema, trismus, hyperemia, intra- and extra-oral fistulated area, and "gnawing" bone sequestration are the most frequent findings. The diagnosis is made in the presence of signs, symptoms and radiographic findings, and can be complemented by CT, magnetic resonance imaging and scintigraphy. Treatment consists of corticotomy, sequestrectomy and removal of the cause, associated with antibiotic therapy. The objective of this work is to present a clinical case of chronic suppurative osteomyelitis in an 8-year-old patient, addressing her etiopathogenesis, clinical, radiographic aspects and its treatment.

Keywords: Abscess; Infection; Osteomyelitis.

Introduction

The chronic suppurative osteomyelitis is characterized by inflammation of infectious origin, which invades the bone marrow spaces, reaching the cortical bone and the periosteum, is a well-defined condition in which there is presence of pain and local edema, fistula and hyperthermia [1,2,9,10]. Described since 1957, osteomyelitis of the jaws has as its main etiology dental caries, and it usually occurs as a complication of periodontal odontogenic infections and post-exodontia [2].

Clinically the osteomyelitis presents as an increase in volume of firm consistency, with normal or discreetly erythematous skin and generating facial asymmetry. Radiographically shows a sclerotic bone, dense and radiopaque, with indefinite areas of osteolysis. Bone erosion on the mandible has a "moth-eaten" appearance and the trabecular pattern has several densities, presenting one or more variable-sized, irregularly-shaped radiolucent areas with poorly defined borders and areas of bone sequestration that correspond to regions dense than adjacent normal bone [3,4],

Histologically, there is a benign fibro-osseous pattern with a moderately cellular fibrous stroma, an extensive proliferation of new subperiosteal bone interposed to this stroma, and the chronic inflammatory infiltrate presents diffuse or focal cells. The presence of trabeculation rich in collagen fibers and the discrete presence of inflammatory lymphocytic infiltrate. The necrotic bone separates from adjacent vitalized tissue and becomes surrounded by subacute inflammatory tissue, characterizing bone sequestration [3-5,9].

Treatment of osteomyelitis of the jaws includes removal of the cause such as rupture of the infection, drainage and irrigation, antibiotic therapy being oral and parenteral (oral, clindamycin 150 mg, clindamycin 300 mg, Amoxicillin 500 mg associated with Metronidazole 400 mg, Cephalosporin first generation, Amoxicillin + Clavulanate, parenteral ceftriaxone 1 g twice daily and metronidazole 100 ml three times daily), extraction of teeth, debridement and removal of necrotic bone tissue, it is also possible to use laser therapy with hyperbaric oxygen, especially mandibular irradiation [4,5,9,10,12-14].

Case Report

Patient MCSL, female, 08 years old, living in the city of Grajaú, Maranhão, Brazil, was referred to the Stomatology clinic of the Faculty of Dentistry, FACIMP - Imperatriz, presenting as main complaint a volumetric increase in left hemiface after extraction of the tooth 36. The patient had previously attended a particular dental clinic with a possible diagnosis of alveolar tooth abscess as a possible diagnosis.

It was reported by the mother in the anamnesis that the patient presented abnormal growth of the face with clinical evolution of 06 months after extraction of the dental element 36. At the oral examination, facial asymmetry was observed due to edema, presence of pain, hyperthermia, redness and cutaneous fistula, so oral functions were compromised due to the volumetric increase and the presence of pain, there were no significant alterations in the nose, ear and eyes and regional lymph nodes. At physical exam, the lesion presented as a bulging in the alveolar ridge of the mandible in the region of molars, with purple coloration, of smooth and shiny surface, with irregular borders, measuring approximately 1 cm in its largest diameter (Figure 1).

Panoramic exam revealed an image of mixed density was observed in the posterior alveolar ridge of the mandible. A cone beam computed tomography (CBCT) was requested, showing mixed density images in the alveolar ridge, irregularity of the alveolar process of the left mandibular corpus region and the local basilar cortical bone with presence of kidnappings, presenting a " moth-eaten "typical of osteomyelitis. Axial sections show diffuse hypodensity intermingling a large part of the alveolar process and mandible body, and a periosteal reaction of the vestibular cortex (Figures 2). Accordingly, to clinical and imaging characteristics of the lesion, the diagnostic hypothesis of chronic suppurative osteomyelitis was suggested.

Since the character of the lesion was benign, the patient was referred to the Municipal Hospital of Imperatriz, Maranhão, Brazil, where she stayed one week receiving antibiotic therapy, and after regression of the edema, she was submitted to the surgical procedure for tissue curettage necrotic (Figure 3). After 2 months, the patient returned for reassessment and presented with a swelling suggesting a possible allergic reaction to the post-operative amoxicillin 500 mg capsule, however, when the lesion regressed, and we were successful in the treatment.

Figure 1: Oral examination of the Patient.

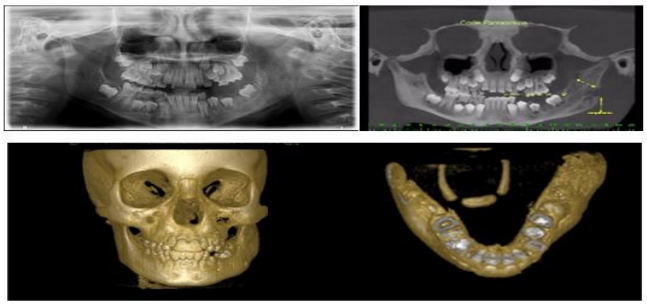

Figure 2: Computed tomography imaging of the lesion.

Figure 3: Surgical procedure for tissue curettage necrotic.

Discussion

Chronic suppurative osteomyelitis (CSO) may be the consequence of an infection of low virulence or chronification of the acute form of the lesion. Otherwise, acute exacerbations of a chronic process may occur, swellings may be present or not. The formation of fistulas occurring for months or even years [6].

The CSO have an anatomical location with a higher incidence in the mandible in relation to the maxilla, especially in molar areas [2,7], coinciding with the case in question, and it is believed that aerobic and anaerobic microorganisms (Staphylococcus, Enterococcus, Streptococcus, Pretovella, Porphyrmonose actinomyces) are responsible for the vast majority of cases of chronic osteomyelitis [8-11].

Most cases of mandibular osteomyelitis are attributed to debridement, removal of kidnappings and antibiotic therapy. This is an infectious nature and is directly dependent on the virulence of the microorganisms involved and the patient's resistance, anatomical location, immunological, nutritional status, age of the patient and the presence of predisposing factors that include: Periapical inflammation (resulting from devitalised teeth), extractions, periodontal disease and fractures that communicate with the skin or mucosa, resulting in a solution of continuity, coinciding with the case of this article, in which the patient presents poor conditions of oral hygiene, which corroborates the various lesions of caries , which was the factor that resulted in the extraction of the element 36 and predisposed to the injury [5-7,9].

Based on the literature findings on antibiotic therapy in cases of CSOs, we have clindamycin 150 mg orally, clindamycin 300 mg, it is chosen because of its broad spectrum of antibacterial action, including anaerobic microorganisms and its potential for penetration, consequently reaching high concentration levels in the bone [10,14]. First-generation cephalosporin and clindamycin for two weeks proved to be effective in treatment, as well as amoxicillin clavulanate [12], amoxicillin 500 mg associated with metronidazole 400 mg for seven days this approach achieved good results with no signs of relapse in the first 6 months [13], cephalosporin third generation (ceftriaxone 1 g) twice daily and metronidazole 100 ml three times a day, also proved to be effective, based on culture sensitivity reports [9], all reported the need to combine antibiotic therapy and surgical debridement to treatment is effective in cases of CSO. Among the indicated treatments, the curettage of the lesion associated with antibiotic therapy is the most advised, as they should extend throughout the soft tissues and devitalized bone for successful treatment, as well as systemic use of antimicrobials, usually of ample spectrum of action. This being the protocol followed for the case cited [1,6,8,9].

Final Considerations

Osteomyelitis is an acute, subacute or chronic progressive inflammatory process that involves the bone, begins by the bone marrow, spreads and extends to the neighbouring soft tissues. Early diagnosis and correct treatment is the basis to ensure recovery and decrease in the number of recurrences. In the present study, we obtained as a therapeutic intervention surgery intervention associated with antibiotic therapy, since chronic suppurative osteomyelitis has marked necrotic involvement of the bone, and it must be removed for the success of the treatment.

References

1. Ribeiro ALR, Mendes FRO, Melo MM, et al. Treatment of Chronic suppurative osteomyelitis of jaw in Child with short period of hospitalization. Rev. Cir. Oral and maxillofacial Traumatology, Camaragibe 2009; 9: 9-16.
2. Acevedo JFO, Caballero MLT. maxillary and mandibular Osteomyelitis in pediatric patients, Med Per 2003.
3. Lima ENA, Carvalho CHP, Pereira JS, et al. Diffuse Sclerosing osteomyelitis reported in diabetic patient, Rev. Cir. Traumatol. Buco-Maxilo-FAC., Camaragibe 2010; 10: 19-23.
4. Silva MM, Castro AL, Castro EVFL, et al. Osteomyelitis of Garré. Theme update and report of two new clinical cases. Rev Brazilian, Rio de Janeiro 2009; 66: 8-11.
5. Rodrigo A, Souza, LN, Souza, ACRA. Chronic suppurative Osteomielitis in the upper jaw: report of a case. Advances En Odontoestomatología 2010; 6: 26.
6. Marcucci G, Junior OC. Fundamentals of Stomatology, Dentistry Publisher 2005; 162-164.
7. Masocatto DC, Oliveira MM, Mendonça JCG. Chronic mandibular Osteomyelitis: a case report, Arch Health Invest 2017; 6: 48-52.
8. Nogueira PTBC, Cardoso AB, Branco BLC, et al. Approach to Chronic suppurative osteomyelitis in mandible: a case report. Braz J Surg Clin Res 2016; 15: 70-74.
9. Mehra H, Gupta S, Gupta H, et al. Chronic suppurative osteomyelitis of mandible: a case report.

Craniomaxillofac Trauma Reconstruction 2013; 6: 197-200.

10. Kumar GR, Syed BA, Prasad N, et al. Chronic Suppurative Osteomyelitis of Subcondylar Region: A Case Report, Int J Clin Pediatr Dent 2013; 6: 119-123.
11. Goda A, Maruyama F, Michi Y, et al. Analysis of the factors affecting the formation of the microbiome associated with chronic osteomyelitis of the jaw. Clin Microbiol Infect 2014; 20: O309-O317.
12. Park J, Myoung H. Chronic suppurative osteomyelitis with proliferative periostitis related to a fully impacted third molar germ: a report of two cases. J Korean Assoc Oral Maxillofac Surg 2016; 42: 215-220.
13. Oliveira TI, de Carli ML, Ribeiro Junior NV, et al. Maxillary chronic osteomyelitis caused by domestic violence: a diagnostic challenge. Case Rep Dent 2014; 930169.
14. Yeoh SC, MacMahon S, Schifter M. Chronic suppurative osteomyelitis of the mandible: case report. Aust Dent J 2005; 50: 200-203.

This manuscript was peer-reviewed
Mode of Review: Single-blinded
Academic Editor: Dr. Lopez Dayami

Copyright: ©2018 Araujo JB. This article is distributed under the terms of the Creative Commons Attribution 4.0 International License [http://creativecommons.org/licenses/by/4.0/], which permits unrestricted use, distribution, and reproduction in any medium, provided you give appropriate credit to the original author[s] and the source, provide a link to the Creative Commons license, and indicate if changes were made.